

# Ozone therapy: a potential therapeutic adjunct for improving female reproductive health

Zaher Merhi<sup>1,2,\*</sup>, Bhavika Garg<sup>2</sup>, Rajean Moseley-LaRue<sup>3</sup>, Amber Ray Moseley<sup>3</sup>, André Hugo Smith<sup>3</sup>, John Zhang<sup>2</sup>

<sup>1</sup> Department of Biochemistry, Albert Einstein College of Medicine, Bronx, NY, USA

<sup>2</sup> New Hope Fertility Center, New York, NY, USA

<sup>3</sup> Hocatt USA LLC, Weatherford, TX, USA

\*Correspondence to: Zaher Merhi, MD, HCLD, zom00@hotmail.com.

## Abstract

Ozone is emerging as a new adjunct therapeutic agent for female infertility. We here present a review of the literature, to date, pertaining to the effect of ozone therapy on tubal, ovarian, endometrial, and vaginal factors that could potentially affect female fertility. It also presents data pertaining to the relationship of ozone therapy on pelvic adhesion formation. Most data were performed on animals and very few human studies existed in the literature. Results suggested that ozone therapy could have beneficial effect on tubal occlusion, could protect from endometritis and vaginitis, might protect ovaries from ischemia and oocyte loss and finally might lead to less formation of pelvic adhesions. There is a critical need for human studies pertaining to ozone therapy, especially using safe methods of administration, such as transdermally or intravaginally, on female fertility.

**Key words:** ozone therapy; reproduction; ovary; uterus; vagina; infertility; fallopian tube; adhesions; oocyte

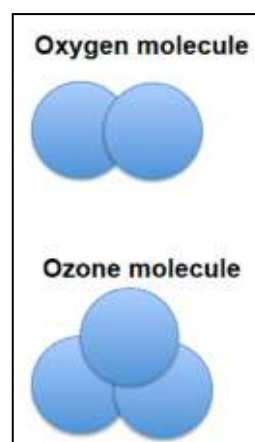
**doi:** 10.4103/2045-9912.260652

**How to cite this article:** Merhi Z, Garg B, Moseley-LaRue R, Moseley AR, Smith AH, Zhang J. Ozone therapy: a potential therapeutic adjunct for improving female reproductive health. *Med Gas Res.* 2019;9(2):101-105.

## INTRODUCTION

Ozone is normally present as a gas made of three atoms of oxygen with a cyclic structure (**Figure 1**).<sup>1</sup> Ozone is an elemental form of oxygen occurring naturally in the Earth's atmosphere<sup>2</sup> surrounding the earth and shielding it from the damaging solar ultraviolet radiation.<sup>2</sup> Ozone is a much stronger oxidant than oxygen, and is unstable at high concentrations to result in its decomposing into oxygen molecules (half-life of 40 minutes at 20°C).<sup>3</sup> It has been shown to break down into two atoms of regular oxygen by giving up an atom of singlet oxygen over a period of 20 to 30 minutes. As a highly reactive molecule, ozone exhibits strong bactericidal, fungicidal, antiviral, and anti-protozoal activities.<sup>3-6</sup> In aqueous form, ozone could have therapeutic effects.<sup>7</sup> In fact, ozone was used for the first time to disinfect operating rooms in 1856 and subsequently for water treatment in 1860.<sup>3-6,8</sup> So far, data have shown that ozone could improve several diseases such as abscesses,<sup>9,10</sup> acne,<sup>11</sup> eczema,<sup>12</sup> psoriasis,<sup>13</sup> human immunodeficiency virus and acquired immune deficiency syndrome,<sup>14-17</sup> fibromyalgia,<sup>18</sup> arthritis,<sup>19</sup> asthma,<sup>20</sup> cancers,<sup>7,21</sup> inflammation,<sup>22</sup> cardiac disease,<sup>23</sup> liver disorders,<sup>24,25</sup> uveitis,<sup>26</sup> cystitis,<sup>27</sup> chronic wounds,<sup>28</sup> dyslipidemia,<sup>29</sup> osteomyelitis,<sup>30</sup> Raynaud's disease,<sup>31</sup> sepsis,<sup>32</sup> and sinusitis.<sup>33</sup>

Some of the mechanisms for ozone's therapeutic actions include the generation of peroxides by ozonolysis with unsaturated fatty acids in cell membranes, activation or generation of reactive oxygen species which function as physiological enhancers of various biological processes (including increased production of adenosine triphosphate), and increased expression of intracellular enzymes with antioxidant activity.<sup>34,35</sup>



**Figure 1: Schematic diagram of the molecular structure of ozone.**

Note: Ozone is made up of three oxygen atoms, while the oxygen in the air is made up of only two atoms.

## SEARCH STRATEGY AND DATA EXTRACTION

A review was performed for all available basic science, experimental animal studies, and clinical peer-reviewed articles including prospective, retrospective, and review articles published in PubMed and Google Scholar until October 2018. Data were extracted from the text, tables and graphs in the manuscripts. The keywords search used included "ozone and pelvic adhesions," "ozone and infertility," "ozone and ovary," "ozone and uterus," and "ozone and vagina."

## SUMMARY OF FINDINGS

### Ozone could help in the treatment of female infertility

#### Tubal factor

Fallopian tubal occlusion is a major cause of female infertility.<sup>35</sup> In one study, 400 infertile women with tubal obstruction were given tubal recanalization using either ozone or saline



(control) treatment.<sup>36</sup> The results showed that postoperative distal tube recanalization rate (rate of clearing blockages) were significantly higher in the ozone group (56%) than in the control group (45%;  $P < 0.01$ ). Six months after the intervention, the overall recanalization rate was significantly higher in ozone group (93%) than control (79%;  $P < 0.01$ ). Additionally, the re-adhesion rates were significantly lower in the ozone group compared to the control group ( $P < 0.01$ ). More importantly, the pregnancy rate after 12 months of the intervention was significantly higher in the ozone group (59%) compared to the control group (43%;  $P < 0.05$ ).<sup>36</sup> These findings suggested that ozone therapy could represent a potential therapeutic agent for women with tubal infertility. Whether this treatment helps women avoid undergoing the costly assisted reproductive technology remains to be determined.

Pelvic inflammatory disease (PID) is a common condition that is characterized by infection and inflammation of the female upper genital tract, thus affecting the fallopian tubes (causing blockage and tubal infertility), uterus and adjacent pelvic structures. PID can also cause chronic pelvic pain and ectopic pregnancy. One study aimed at demonstrating the significant inhibition of PID as a result of the administration of ozone injected through the pelvic cavity in female rats.<sup>37</sup> Mixed bacteria consisting of *Staphylococcus aureus*, *Escherichia coli*, and *M. urealyticum* were used to establish the acute PID female rat model. A grinding needle was pulled and drawn in the uterine cavity on several occasions to cause mechanical injury to the endometrial tissues. Antibiotics (levofloxacin) or ozone at concentrations of 45  $\mu\text{g}/\text{mL}$  and 60  $\mu\text{g}/\text{mL}$  was injected continuously for 7 days into the pelvic cavity of the rats with PID. Serum levels of interleukin (IL)-6, tumor necrosis factor (TNF)- $\alpha$ , intercellular cell adhesion molecule-1, immunoglobulin G (IgG), IgA and IgM, and complement C3 and C4 were measured. The uteri were removed and analyzed for endometrial inflammation. The results showed that IL-6 serum level in PID rats decreased with the increase of ozone concentration. The content of TNF- $\alpha$  and IL-6 decreased while that of IL-2 increased in PID rats injected with 45  $\mu\text{g}/\text{mL}$  or 60  $\mu\text{g}/\text{mL}$  ozone. Immunoglobulin content and immunologic function of PID rats were ameliorated after injection with 45  $\mu\text{g}/\text{mL}$  or 60  $\mu\text{g}/\text{mL}$  ozone, where the contents of IgG, IgA and IgM, C3 and C4, and the E-rosette formation rate and transformation rate of T lymphocyte in rats in the 45  $\mu\text{g}/\text{mL}$  ozone, 60  $\mu\text{g}/\text{mL}$  ozone and levofloxacin groups were markedly increased ( $P < 0.05$ ), the endometrial injury in PID rats was reduced after injection with 45  $\mu\text{g}/\text{mL}$  or 60  $\mu\text{g}/\text{mL}$  ozone, and finally IL-6 positive expression in the uterine tissue of PID rats was reduced after injection with 45  $\mu\text{g}/\text{mL}$  or 60  $\mu\text{g}/\text{mL}$  ozone. Taken together, the key findings of the study present evidence that ozone may aid in the treatment of PID and can represent a promising therapeutic agent for inflammatory diseases via inhibition of the necrosis of the endometrial epithelial cells and by alleviating the inflammatory reactions.<sup>37</sup>

### Endometrial factor

During childbirth in animals, the barriers of the vagina and cervix could get compromised, which could cause the bacteria to ascend into the genital tract leading to infections. The uterine

inflammation and bacterial infections can disrupt the immune responses between the endometrium and the embryo, causing infertility.<sup>38,39</sup> Ozone has been tested as a possible treatment to reduce the inflammation observed in endometritis.<sup>3</sup> A study in cows assessed whether fertility rates increased postpartum following intrauterine ozone administration.<sup>40</sup> In that study, one group of cows were treated with ozonated foam into the uterus within 6 hours after calving and 24 hours later while the control group received no treatment. There was a voluntary waiting period for estrus to occur. Semen from six bulls of the Simmental breed was used equally between animals. Artificial inseminations were performed daily using thawed frozen semen until ovulation. The success of the treatment was measured by the number of days open (before achieving pregnancy) and the number of artificial inseminations needed to achieve pregnancy. Cows in the ozone treatment group had 1.3 times fewer days open and an average of 1.44 times fewer artificial inseminations until pregnancy compared to the control group ( $P < 0.05$ ). The authors hypothesized that it is plausible that ozone therapy, *via* decreasing inflammation related to endometritis, could lead to healthier endometrial environment. In order to determine the influence of preventive application of two different ozone preparations (foam spray *versus* pearls) on reproductive efficiency in dairy cows with physiological puerperium,<sup>41</sup> ozone pearls or ozone foam spray or no treatment (control group) was administered to cows during early puerperium, 24–48 hours after parturition. Artificial inseminations were performed using frozen-thawed semen. Assessment of reproductive outcome was done by monitoring the interval from calving to first insemination (days open to first service), relative pregnancy rate, first service conception rate, and all service conception rate. The relative rate of first service decreased in the control group by 38%. Cows treated with ozone spray became pregnant earlier and had better first service conception rate and all service conception rate. That study suggested that preventive ozone intrauterine application during early puerperal period, especially the foaming spray form of ozone preparations, improved the reproductive potential in dairy cows.

Another study evaluated uterine infections following dystocia and retained placenta by comparing the effect of ozone therapy to traditional antibiotic treatment in 139 ewes.<sup>42</sup> In that study, there were five groups: control, retained placenta with ozone, retained placenta with antibiotics, dystocia with ozone, and dystocia with antibiotics groups. Ozone foam spray was applied into the body of the uterus for 2–3 seconds and intrauterine tablets of oxytetracycline hydrochloride were administered. The investigators measured the effect of the treatments by measuring the transversal uterine diameter using transrectal ultrasonography. Their findings demonstrated that the average transversal diameter of the uterus in the retained placenta with ozone group was higher (5.39 cm) than that in the control group (4.98 cm), and lower than that in the retained placenta with antibiotics group, which had a diameter of around 5.55 cm. The ozone treatment achieved better results than antibiotics therapy. There was a difference in the uterine diameter 25 days postpartum between the retained placenta with ozone and retained placenta with antibiotics groups ( $P < 0.05$ ), but there



was no difference in dystocia. That study showed that ozone preparations did not cause any negative side effects and seemed to be as effective, but not better than antibiotics.<sup>42</sup>

Retention of fetal membrane, the failure of fetal membrane removal within 6 to 8 hours after birth, is a post-parturient complication that might adversely affect reproductive potential due to endometrial factor. One study compared the efficiency of ozone therapy to antibiotics for retention of fetal membrane treatment in goats where they were treated with either ozone foam spray ( $n = 21$ ) or with foaming oxytetracycline tablets ( $n = 20$ ).<sup>43</sup> Goats in both groups were mated successfully and became pregnant in the next kidding season. More specifically, the average parity and conception rates were similar. There was no significant difference in the average number of kids per ewe between the ozone therapy and antibiotics groups ( $P > 0.05$ ).<sup>43</sup> That study highlights the advantage of using ozone therapy instead of antibiotics because it avoids the incidence of bacterial resistance in consumers of foodstuffs of goat origin, and there is no withdrawal period for milk, meat and other tissues.

### **Vaginal factor**

One of the causes of infertility is inflammation of the genitalia. A study tested the effect of ozone therapy in infertile women of inflammatory etiology.<sup>44</sup> There were two treatment groups: primary infertility and secondary infertility. Women ( $n = 56$ , 50 of whom had infertility) revealed many infections such as chlamydiosis, mycoplasmosis, ureaplasmosis, herpes simplex and cytomegalovirus infection. The patients underwent a 12-day course of ozone therapy that included refraining from sexual intercourse, minor autohemotherapy with ozonated blood, vaginal application with ozonated distilled water, intravenous insufflation of ozonated isotonic normal saline. One hundred percentage of chlamydiosis ( $n = 36$ ) and mycoplasmosis ( $n = 18$ ) infections was eliminated. Most of the ureaplasmosis (30 out of 33 cases) and gardnerellosis (19 out of 21 cases) cases were cured. Five out of seven (71%) patients with herpes simplex and cytomegalovirus infection were cured. Eight out of 50 infertile women conceived within three months of the full ozone therapy course. Thus ozone therapy can be very useful in the treatment of genital inflammatory diseases potentially improving fertility.

Urovagina is the collection of urine in the cranial portion of vagina, causes pooling of urine around the cervix, ultimately leading to vaginitis and endometritis that potentially lead to lower embryo viability and infertility.<sup>45</sup> One study compared traditional treatment to ozone therapy<sup>46</sup> where 1219 cows with urovagina were treated with either saline (control) flush, or antibiotics (streptomycin) flush, or ozone therapy flush within the vagina and the uterus. Each group was inseminated up to five times until pregnancy (insemination with frozen sperm from two bulls to keep the lowest possible number of variations). If the cows were not pregnant by the fifth artificial insemination, they were then deemed infertile and culled (sent to be slaughtered). The success of the treatment was measured by the number of days open (before achieving pregnancy) and the number of artificial inseminations needed to achieve pregnancy. The group that received ozone therapy

flush had the shortest period of days open, the fewest number of inseminations until pregnancy and the smallest number of culled cows ( $P < 0.05$  for all). These findings indicated that ozone therapy flush coupled with intracornual insemination presents an effective treatment option for urovagina and could lead to successful pregnancies.

### **Ovarian factor**

Ovarian torsion is not an uncommon problem in reproductive-aged women and it causes a reduced blood flow to the ovary causing oocyte death and lower fertility especially when the treatment involves oophorectomy.<sup>47,48</sup> Patients can be treated by detorsion of the adnexa to preserve the ovary but this causes several negative consequences, like ischemia/reperfusion injuries. Ischemia leads to increased levels of lactic acid and hypoxanthine while reperfusion causes the formation of free oxygen radicals, which cause abnormal pathologic changes in the ovarian tissue.<sup>48</sup> A study in rats investigated the effect of ozone therapy in ovarian ischemia/reperfusion injury.<sup>49</sup> There were three groups of animals: a sham group (controls) where the right ovary was fixed and removed after 2 hours, a torsion group where the right ovary underwent 720° torsion for 2 hours, followed by 2 hours reperfusion and then oophorectomy and the ozone group which underwent 720° torsion for 2 hours, then ozone therapy was given for 10 minutes before reperfusion, 2 hours reperfusion and then oophorectomy. Tissue samples were analyzed for malondialdehyde (MDA), nitric oxide, and total sulfhydryl levels. Examination of the ovarian and periovarian sections was performed to determine the levels of congestion, hemorrhage, interstitial edema, and polymorphonuclear neutrophilic infiltrations. There was no significant difference observed between the sham group and the torsion group ( $P > 0.05$ ). The ozone group had increased levels of nitric oxide, which could be ovary-protective after torsion, and also showed decreased levels of congestion and interstitial edema. MDA levels were significantly lower in the ozone group compared to the torsion and sham groups, but nitric oxide and total sulfhydryl values were higher in the ozone group compared to the torsion group ( $P < 0.05$ ). Finally, MDA levels were lower in the ozone group compared to the sham group ( $P < 0.05$ ) and no difference was present in nitric oxide and total sulfhydryl between the ozone group and sham group ( $P > 0.05$ ). These results suggested that ozone therapy might decrease ischemia/reperfusion injury thus offering an option to an ovary-sparing approach to ovarian torsion.<sup>49</sup>

A similar study investigated the effect of two antioxidant agents, ozone and ellagic acid, on ischemia/reperfusion injuries developed from ovarian torsion-detorsion animal model.<sup>50</sup> Ellagic acid has antioxidant and anti-inflammatory effects. In that study, rats were sacrificed then their ovarian tissue samples were histopathologically examined for MDA, glutathione reductase, catalase, and superoxide dismutase (SOD) levels. Tissue damages represented by hemorrhage, congestion, edema, and inflammation were also examined. The MDA, glutathione reductase, and catalase values of the ischemia/reperfusion group were significantly higher compared to the control group ( $P < 0.001$ ). The antioxidant enzyme activity and MDA levels in the ovarian tissue decreased in the ozone,

ellagic acid and ozone + ellagic acid groups ( $P < 0.05$ ). Histopathological examination revealed that tissue damage in the ozone, ellagic acid and ozone + ellagic acid groups decreased in comparison with the ischemia/reperfusion group ( $P < 0.05$ ). Thus, these results showed that both ozone and ellagic acid, used separately or together, can be useful in the treatment of ovarian tissue injury due to ischemia/reperfusion.<sup>50</sup>

### Pelvic adhesions

Ischemia or peritoneal injuries can cause postoperative intra-abdominal adhesions, which could result in pelvic pain and potentially infertility.<sup>51</sup> It is well known that oxidative stress plays an important role in adhesion formation<sup>51</sup> while ozone therapy reduces inflammation and increases antioxidant enzyme activities like glutathione peroxidase and SOD activity by altering reactive oxygen species production.<sup>1</sup> One study evaluated the efficacy of ozone therapy in a female Wistar rat model of experimental uterine adhesion (EUA) by using bipolar coagulation on the uterine horns and corresponding pelvic sidewall parietal peritoneum. The investigators hypothesized that ozone therapy might have protective effects on postoperative intra-abdominal adhesions. There were three groups of animals in that study: sham, EUA, and EUA + ozone therapy groups. The ozone therapy was given intraperitoneally at 0.7 mg/kg daily as a single dose for 3 days following by measurement of uterine parameters including MDA, SOD, and glutathione peroxidase levels and peritoneal fluid TNF- $\alpha$  levels. The results showed that the EUA + ozone therapy group had significantly lower macroscopic adhesion score and lower peritoneal TNF- $\alpha$  levels compared to the EUA group ( $P < 0.001$ ). The alterations in uterine MDA, SOD and glutathione peroxidase induced by EUA were all significantly reversed by ozone therapy ( $P < 0.001$ ,  $P = 0.003$ ,  $P = 0.002$ ; respectively). The authors concluded that ozone therapy could attenuate postoperative uterine adhesions by modulating TNF- $\alpha$  levels and by altering the oxidative state.

## CONCLUSION

The current literature showed that most of the studies to date were performed on animal models and that there is a critical need to assess the effect of ozone, administered safely and particularly given transdermally and vaginally, on female reproduction (Figure 2). Future studies should be prospective in nature and should assess the impact of ozone therapy on oocyte quality and quantity in women undergoing fertility treatment, especially those who had poor prognosis due to low ovarian reserve. Additionally, since having a thin endometrial lining is not uncommon during fertility treatment and since this problem could be frustrating for both physicians and their patients, it is worthwhile developing studies to evaluate the action of ozone on thickening the endometrial lining especially that ozone causes vasodilatation and increases tissue blood flow. Finally, it was noted that no studies to date have considered ozone therapy in the setting of unexplained recurrent pregnancy loss, a problem where efforts to date has not shown any promise; thus studies testing ozone therapy as a potential therapeutic agent in this setting are critically needed.

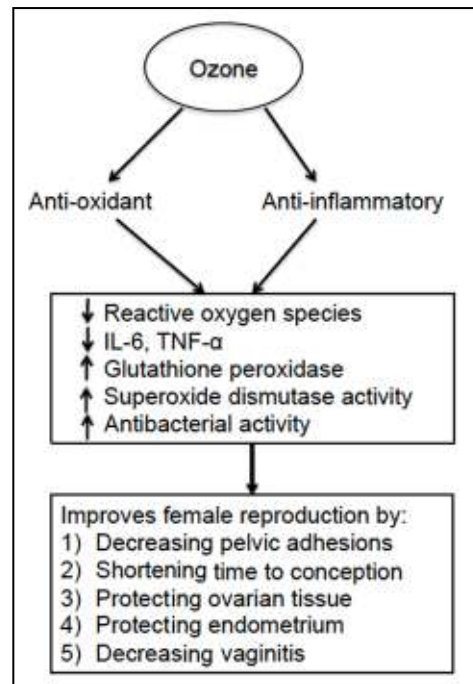


Figure 2: Mechanisms by which ozone might improve female reproduction. Note: IL-6: Interleukin-6; TNF- $\alpha$ : tumor necrosis factor- $\alpha$ .

### Author contributions

The authors contributed to the development and writing of the manuscript. Literature search: ZM, BG, JZ; topic development: RML, ARM, AHS; manuscript writing, figures production: ZM, BG, JZ, RML, ARM, AHS. ZM, BG, and JZ approved the final version of the manuscript.

### Conflicts of interest

AHS is the founder and Co-CEO of HOCATT USA. ARM is the Chief Executor Officer of Hocatt USA. RML is the Chief Operational Officer and Medical Director of Hocatt USA. ZM acts as a paid consultant for Hocatt USA, but he was not paid to write this manuscript. JZ and BG have nothing to disclose.

### Financial support

None.

### Copyright license agreement

The Copyright License Agreement has been signed by all authors before publication.

### Plagiarism check

Checked twice by iThenticate.

### Peer review

Externally peer reviewed.

### Open access statement

This is an open access journal, and articles are distributed under the terms of the Creative Commons Attribution-NonCommercial-ShareAlike 4.0 License, which allows others to remix, tweak, and build upon the work non-commercially, as long as appropriate credit is given and the new creations are licensed under the identical terms.

## REFERENCES

1. Bocci VA. Scientific and medical aspects of ozone therapy. State of the art. *Arch Med Res*. 2006;37:425-435.
2. Cicerone RJ. Changes in stratospheric ozone. *Science*. 1987; 237:35-42.
3. Đuričić D, Valpotić H, Samardžija M. Prophylaxis and therapeutic potential of ozone in buiatrics: Current knowledge. *Anim Reprod Sci*. 2015;159:1-7.
4. Yamayoshi T, Tatsumi N. Microbicidal effects of ozone solution on methicillin-resistant *Staphylococcus aureus*. *Drugs Exp Clin Res*. 1993;19:59-64.



5. Sugita H, Asai T, Hayashi K, et al. Application of ozone disinfection to remove *Enterococcus seriolocida*, *Pasteurella piscicida*, and *Vibrio anguillarum* from seawater. *Appl Environ Microbiol.* 1992;58:4072-4075.
6. Sato H, Wananabe Y, Miyata H. Virucidal effect of ozone treatment of laboratory animal viruses. *Jikken Dobutsu.* 1990;39:223-229.
7. Clavo B, Santana-Rodríguez N, Llontop P, et al. Ozone therapy as adjuvant for cancer treatment: is further research warranted? *Evid Based Complement Alternat Med.* 2018;2018:7931849.
8. Kashiwagi K, Saito K, Wang YD, Takahashi H, Ishijima K, Tsukahara S. Safety of ozonated solution as an antiseptic of the ocular surface prior to ophthalmic surgery. *Ophthalmologica.* 2001;215:351-356.
9. Karatieva S, Plesh I, Yurkiv O, Semenenko S, Kozlovskaya I. New method of treatment of pyoinflammatory soft tissue complications in patients with diabetes mellitus. *Georgian Med News.* 2017:58-60.
10. Li B, Liu C, Wang L, et al. The value of ozone in CT-guided drainage of multiloculated pyogenic liver abscesses: a randomized controlled study. *Can J Gastroenterol Hepatol.* 2018;2018:1236974.
11. Gloor M, Lipphardt BA. Studies on ozone therapy of acne vulgaris. *Z Hautkr.* 1976;51:97-101.
12. Kosheleva IV, Kulikov AG. Effectiveness of complex therapy of eczema patients with the use of various methods of ozone therapy. *Vopr Kurortol Fizioter Lech Fiz Kult.* 2001:40-42.
13. Evstigneeva IS, Kulikov AG, Yarusovskaya OV, Shakhova AS, Lutoshkina MG. Physical therapy of psoriasis. The modern methodological approaches. *Vopr Kurortol Fizioter Lech Fiz Kult.* 2018;95:53-58.
14. Garber GE, Cameron DW, Hawley-Foss N, Greenway D, Shannon ME. The use of ozone-treated blood in the therapy of HIV infection and immune disease: a pilot study of safety and efficacy. *AIDS.* 1991;5:981-984.
15. Carpendale MT, Freeberg J, Griffiss JM. Does ozone alleviate AIDS diarrhea? *J Clin Gastroenterol.* 1993;17:142-145.
16. Frankum B, Katelaris CH. Ozone therapy in AIDS--truly innocuous? *Med J Aust.* 1993;159:493.
17. Oxygen plus ozone inactivate HIV. *AIDS Patient Care.* 1994;8:167.
18. Hidalgo-Tallón J, Menéndez-Cepero S, Vilchez JS, Rodríguez-López CM, Calandre EP. Ozone therapy as add-on treatment in fibromyalgia management by rectal insufflation: an open-label pilot study. *J Altern Complement Med.* 2012;19:238-242.
19. Raeissadat SA, Rayegani SM, Forogh B, Hassani Abadi P, Moridnia M, Rahimi Dehgolan S. Intra-articular ozone or hyaluronic acid injection: Which one is superior in patients with knee osteoarthritis? A 6-month randomized clinical trial. *J Pain Res.* 2018;11:111-117.
20. Turner CR, Kleeburger SR, Spannhake EW. Preexposure to ozone blocks the antigen-induced late asthmatic response of the canine peripheral airways. *J Toxicol Environ Health.* 1989;28:363-371.
21. Dogan R, Hafiz AM, Kiziltan HS, et al. Effectiveness of radiotherapy+ozone on tumoral tissue and survival in tongue cancer rat model. *Auris Nasus Larynx.* 2018;45:128-134.
22. Kucukgul A, Erdogan S, Gonenci R, Ozan G. Beneficial effects of non-toxic ozone on H<sub>2</sub>O<sub>2</sub>-induced stress and inflammation. *Biochem Cell Biol.* 2016;94:577-583.
23. Buyuklu M, Kandemir FM, Set T, et al. Beneficial effects of ozone therapy on oxidative stress, cardiac functions and clinical findings in patients with heart failure reduced ejection fraction. *Cardiovasc Toxicol.* 2017;17:426-433.
24. Safwat MH, El-Sawalhi MM, Mausouf MN, Shaheen AA. Ozone ameliorates age-related oxidative stress changes in rat liver and kidney: effects of pre- and post-ageing administration. *Biochemistry (Mosc).* 2014;79:450-458.
25. Tezcan AH, Ozturk O, Ustebay S, Adali Y, Yagmurdu H. The beneficial effects of ozone therapy in acetaminophen-induced hepatotoxicity in mice. *Pharmacol Rep.* 2018;70:340-345.
26. Kaya A, Sonmez M, Kar T, et al. Efficiency of ozone therapy in a rat model of experimental uveitis. *Ocul Immunol Inflamm.* 2017;25:700-705.
27. Tasdemir C, Tasdemir S, Vardi N, et al. Evaluation of the effects of ozone therapy on *Escherichia coli*-induced cytitis in rat. *Ir J Med Sci.* 2013;182:557-563.
28. Fitzpatrick E, Holland OJ, Vanderlelie JJ. Ozone therapy for the treatment of chronic wounds: a systematic review. *Int Wound J.* 2018;15:633-644.
29. Di Paolo N, Gaggiotti E, Galli F. Extracorporeal blood oxygenation and ozonation: clinical and biological implications of ozone therapy. *Redox Rep.* 2005;10:121-130.
30. Steinhart H, Schulz S, Mutters R. Evaluation of ozonated oxygen in an experimental animal model of osteomyelitis as a further treatment option for skull-base osteomyelitis. *Eur Arch Otorhinolaryngol.* 1999;256:153-157.
31. Cooke ED, Pockley AG, Tucker AT, Kirby JD, Bolton AE. Treatment of severe Raynaud's syndrome by injection of autologous blood pretreated by heating, ozonation and exposure to ultraviolet light (H-O-U) therapy. *Int Angiol.* 1997;16:250-254.
32. Madej P, Plewka A, Madej JA, et al. Ozone therapy in induced endotoxemic shock. II. The effect of ozone therapy upon selected histochemical reactions in organs of rats in endotoxemic shock. *Inflammation.* 2007;30:69-86.
33. Muminov AI, Khushvakova N. Ozone therapy in patients with chronic purulent frontal sinusitis. *Vestn Otorinolaringol.* 2002:46.
34. Cho M, Chung H, Yoon J. Disinfection of water containing natural organic matter by using ozone-initiated radical reactions. *Appl Environ Microbiol.* 2003;69:2284-2291.
35. Bulletti C, Panzini I, Borini A, Coccia E, Setti PL, Palagiano A. Pelvic factor infertility: diagnosis and prognosis of various procedures. *Ann N Y Acad Sci.* 2008;1127:73-82.
36. He C, Ma X. Distal fallopian tube recanalization using ozone treatment: a clinical study in two hundred tubal obstruction Chinese patients. *Int J Clin Exp Med.* 2015;8:2958-2961.
37. Wei A, Feng H, Jia XM, Tang H, Liao YY, Li BR. Ozone therapy ameliorates inflammation and endometrial injury in rats with pelvic inflammatory disease. *Biomed Pharmacother.* 2018;107:1418-1425.
38. Nash DM, Paddison J, Davies Morel MCG, Barnea ER. Preimplantation factor modulates acute inflammatory responses of equine endometrium. *Vet Med Sci.* 2018;4:351-356.
39. Mitchell CM, Haick A, Nkwopara E, et al. Colonization of the upper genital tract by vaginal bacterial species in nonpregnant women. *Am J Obstet Gynecol.* 2015;212:611.e611-619.
40. Zobel R, Martinec R, Ivanović D, et al. Intrauterine ozone administration for improving fertility rate in Simmental cattle. *Vet Arh.* 2014;84:1-8.
41. Djuricic D, Vince S, Ablondi M, Dobranic T, Samardzija M. Effect of preventive intrauterine ozone application on reproductive efficiency in Holstein cows. *Reprod Domest Anim.* 2012;47:87-91.
42. Đuričić D, Valpotić H, Žura Žaja I, Samardžija M. Comparison of intrauterine antibiotics versus ozone medical use in sheep with retained placenta and following obstetric assistance. *Reprod Domest Anim.* 2016;51:538-540.
43. Djuricic D, Valpotic H, Samardzija M. The intrauterine treatment of the retained foetal membrane in dairy goats by ozone: novel alternative to antibiotic therapy. *Reprod Domest Anim.* 2015;50:236-239.
44. Chandra-D'Mello R, D'Mello R. Therapy in Female Infertility. <https://www.austinozone.com/wp-content/uploads/Ozone-Therapy-and-Female-Infertility.pdf>Ozone 2018.
45. Gautam G, Nakao T. Prevalence of urovagina and its effects on reproductive performance in Holstein cows. *Theriogenology.* 2009;71:1451-1461.
46. Zobel R, Tkalčić S, Štoković I, Pipal I, Buić V. Efficacy of ozone as a novel treatment option for urovagina in dairy cows. *Reprod Domest Anim.* 2012;47:293-298.
47. Kang HJ, Davis OK, Rosenwaks Z. Simultaneous bilateral ovarian torsion in the follicular phase after gonadotropin stimulation. *Fertil Steril.* 2006;86:462.e413-464.
48. Spinelli C, Piscioneri J, Strambi S. Adnexal torsion in adolescents: update and review of the literature. *Curr Opin Obstet Gynecol.* 2015;27:320-325.
49. Aslan MK, Boybeyi Ö, Şenyücel MF, et al. Protective effect of intraperitoneal ozone application in experimental ovarian ischemia/reperfusion injury. *J Pediatr Surg.* 2012;47:1730-1734.
50. Sayar I, Bicer S, Gursul C, Gürbüz M, Peker K, Işık A. Protective effects of ellagic acid and ozone on rat ovaries with an ischemia/reperfusion injury. *J Obstet Gynaecol Res.* 2016;42:52-58.
51. Binda MM, Molinas CR, Koninckx PR. Reactive oxygen species and adhesion formation: clinical implications in adhesion prevention. *Hum Reprod.* 2003;18:2503-2507.

Received: January 27, 2019

Accepted: April 15, 2019